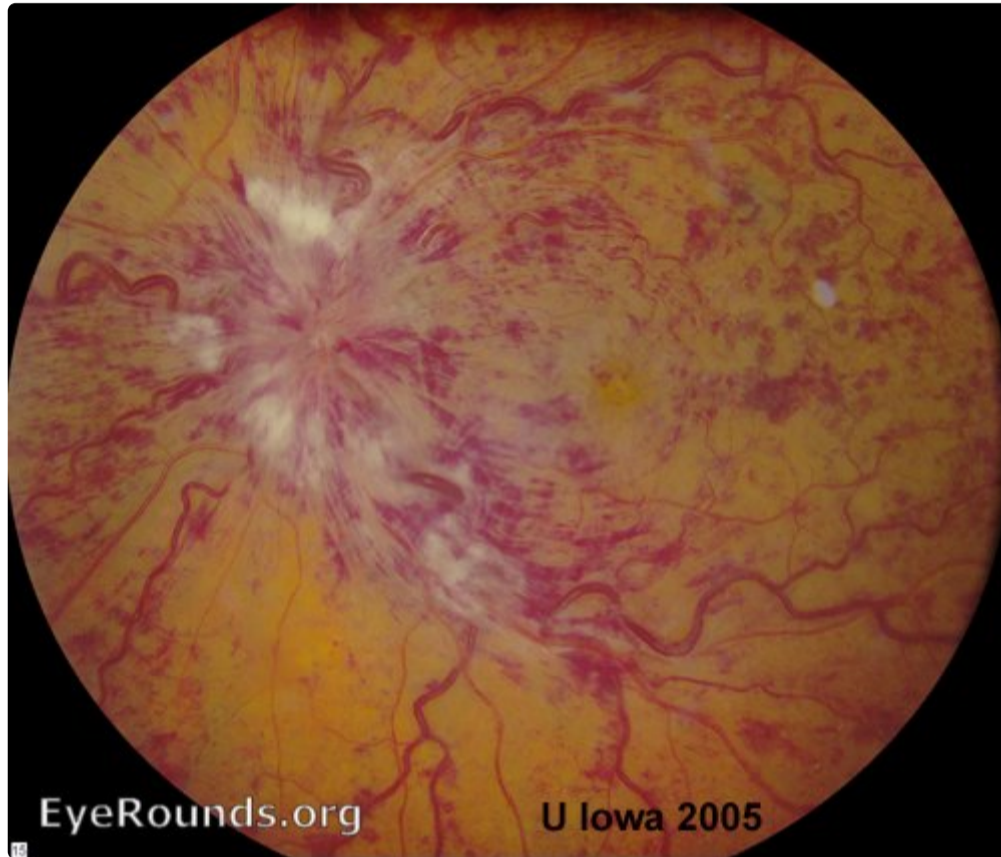


Central Retinal Vein Occlusion (CRVO)

Category(ies): Retina, Vitreous

Contributor: Robert B. Dinn, MD, Erin E. O'Malley, MD, and Stephen R. Russell, MD

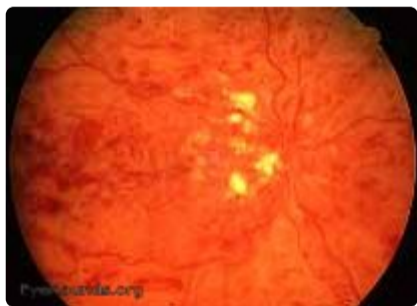

submitted in 2005.

[Enlarge](#) [Download](#)

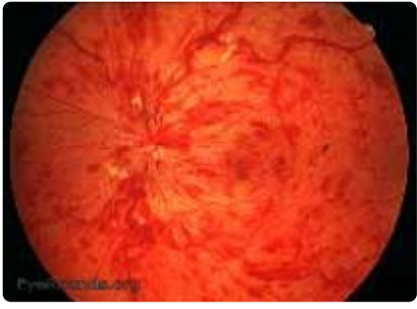Contributor: Andrew Doan, MD, PhD for Sohan Hayreh, MD, PhD

submitted in 2004



1 & 2 Ischemic CRVO

[Enlarge](#) [Download](#)



3& 4 Non-Ischemic CRVO

[Enlarge](#)

[Download](#)

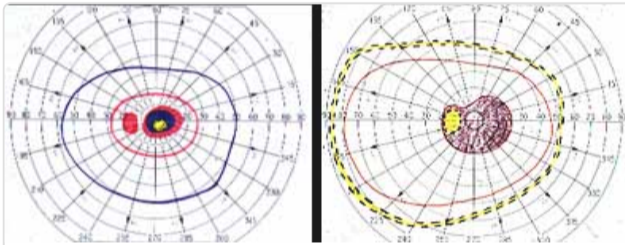
Image Permissions:



Ophthalmic Atlas Images by [EyeRounds.org](#), [The University of Iowa](#) are licensed under a [Creative Commons Attribution-NonCommercial-NoDerivs 3.0 Unported License](#).



Related Articles



[Related Article: CRVO](#)

Address

University of Iowa
Roy J. and Lucille A. Carver College
of Medicine
Department of Ophthalmology and
Visual Sciences
200 Hawkins Drive
Iowa City, IA 52242

[Support Us](#)

Legal

Copyright © 2019 The University of
Iowa. All Rights Reserved
[Report an issue with this page](#)
[Web Privacy Policy](#) |
[Nondiscrimination Statement](#)

Related Links

[Cataract Surgery for Greenhorns](#)
[EyeTransillumination](#)
[Gonioscopy.org](#)
[Iowa Glaucoma Curriculum](#)
[Iowa Wet Lab](#)
[Patient Information](#)
[Stone Rounds](#)
[The Best Hits Bookshelf](#)

EyeRounds Social Media

Follow



Receive notification of new cases,
[sign up here](#)
[Contact Us](#)
[Submit a Suggestion](#)